ANIMAL MODELS OF HUMAN MEMORY

AND HUMAN MEMORY IMPAIRMENT

J. Neurol. Neurosurg. Psychiat., 1957, **20**, 11.

LOSS OF RECENT MEMORY AFTER BILATERAL HIPPOCAMPAL LESIONS

BY

WILLIAM BEECHER SCOVILLE and BRENDA MILNER

From the Department of Neurosurgery, Hartford Hospital, and the Department of Neurology and Neurosurgery, McGill University, and the Montreal Neurological Institute, Canada

In 1954 Scoville described a grave loss of recent memory which he had observed as a sequel to bilateral medial temporal-lobe resection in one psychotic patient and one patient with intractable seizures. In both cases the operations had been radical ones, undertaken only when more conservative forms of treatment had failed. The removals found that undercutting limited to the orbital surfaces of both frontal lobes has an appreciable therapeutic effect in psychosis and yet does not cause any new personality deficit to appear (Scoville, Wilk, and Pepe, 1951). In view of the known close relationship between the posterior orbital and mesial temporal cortices (MacLean, 1952; Pribram and

Mishkin, M. Nature Vol. 273,
25 May 1978

Memory in monkeys severely impaired by combined but not by separate removal of amygdala and hippocampus

THE profound anterograde amnesia that has been attributed in the clinical literature to damage of the hippocampal system[1,2] has not been observed in animals with such damage. Hippocampal-system lesions in animals do markedly impair some forms of spatial memory[3,4], but the effects on other forms of memory have generally seemed minor[5-9] compared with the dramatic disorder described in man[1,2]. This discrepancy between the clinical and animal literature could indicate a true evolutionary shift in the functions of the hippocampus[5,10], or, at the other extreme, it could simply reflect the use of incommensurate measures across species[11,12]. (Strong support for this second interpretation has been provided by Gaffan[13].) A third possibility, however, is that the discrepancy points to inaccurate localisation of the neuropathology in man that is responsible for the profound amnesia. Support for this last alternative comes from new evidence in monkeys indicating that a striking impairment in visual memory can be produced by the combined ablation of the hippocampal formation and the amygdaloid body, but not by ablation of either of these structures alone.

Twelve monkeys (*Macaca mulatta*) weighing from 3.5 to 5 kg were trained preoperatively in a Wisconsin general testing apparatus to perform one-trial object recognition[14] for peanut rewards. The procedure involved presentation of a baited object over the central well of a three-well tray, followed 10 s later by re-presentation of that object (now negative) together with a new object (positive) over the lateral wells. Twenty such trials separated by 30 s intervals were given daily, each trial with a new pair of objects. The successive pairs were drawn randomly from a collection of several hundred unmounted junk objects of diverse sizes, colours, shapes and textures. The testing procedure exploits

DNMS

Motor skill task

Recognition Memory

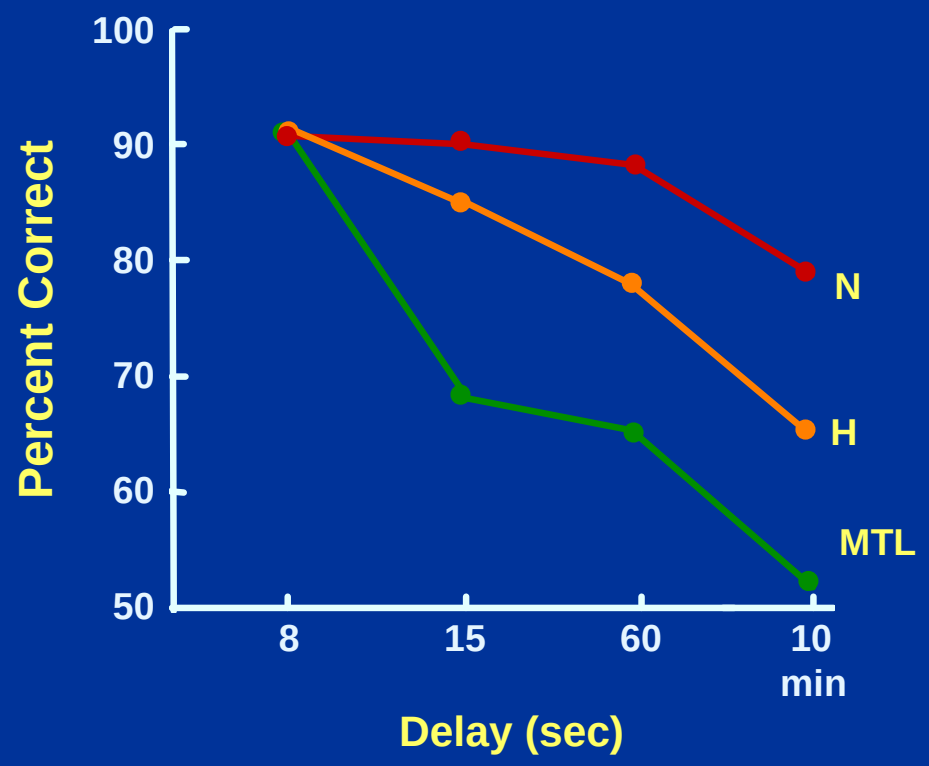

Skill Learning

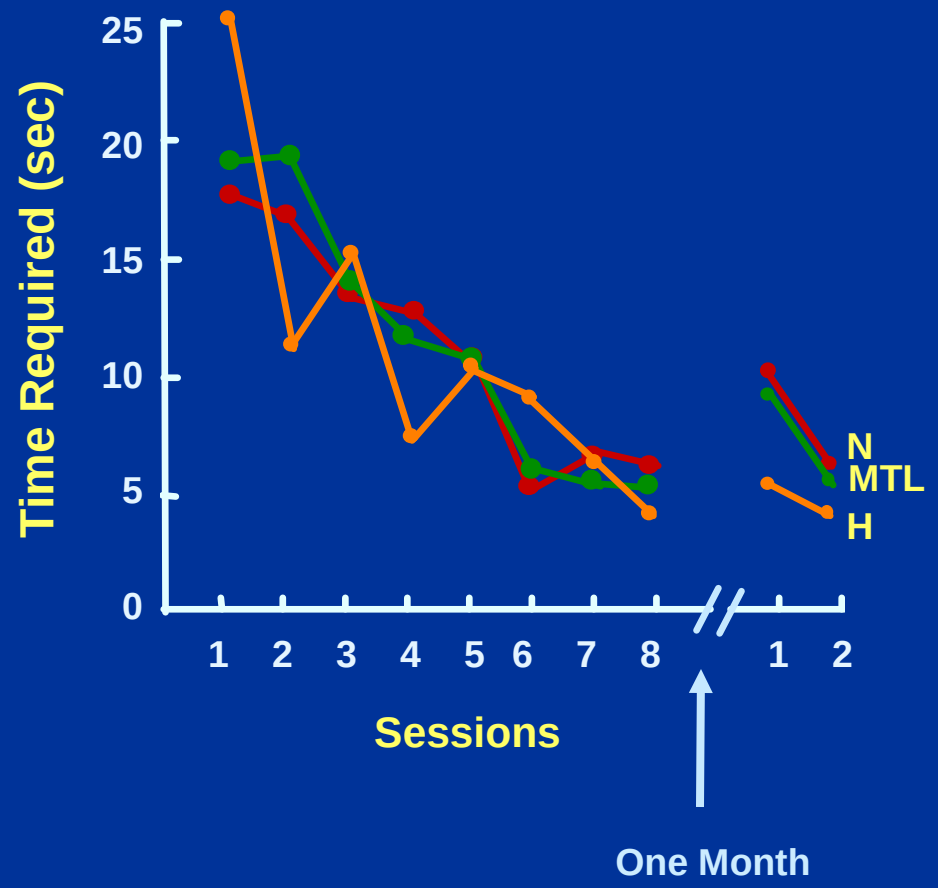

Zola and Squire, J. Neurosci., 1984; Alvarez et al, J. Neurosci., 1995

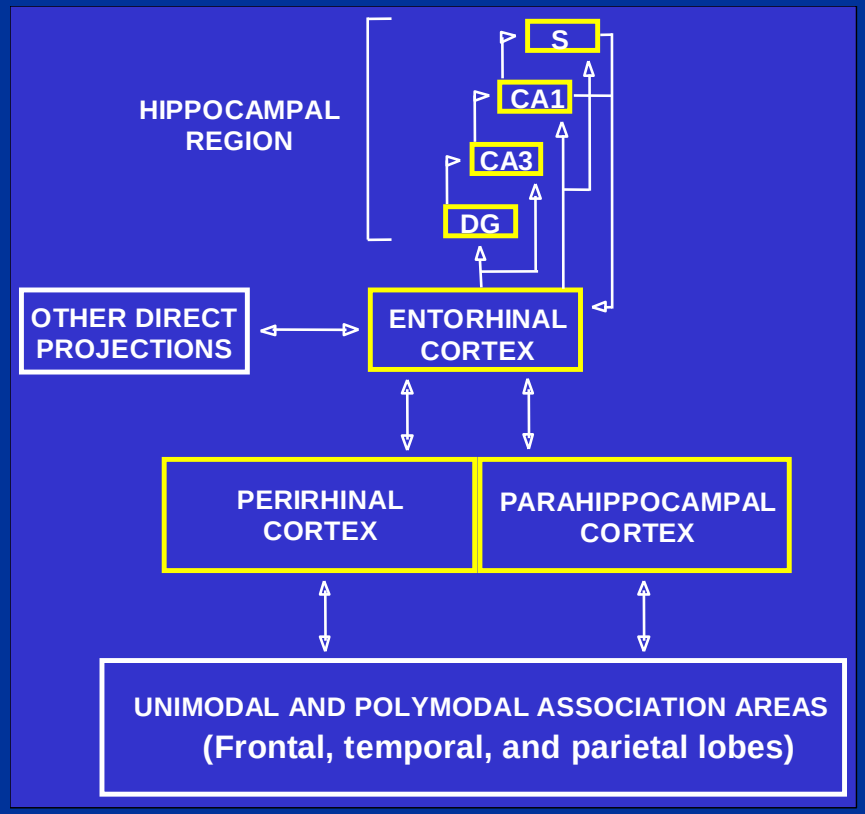
HIPPOCAMPAL REGION
S
CA1
CA3
DG
OTHER DIRECT PROJECTIONS
ENTORHINAL CORTEX
PERIRHINAL CORTEX
PARAHIPPOCAMPAL CORTEX
UNIMODAL AND POLYMODAL ASSOCIATION AREAS
(Frontal, temporal, and parietal lobes)

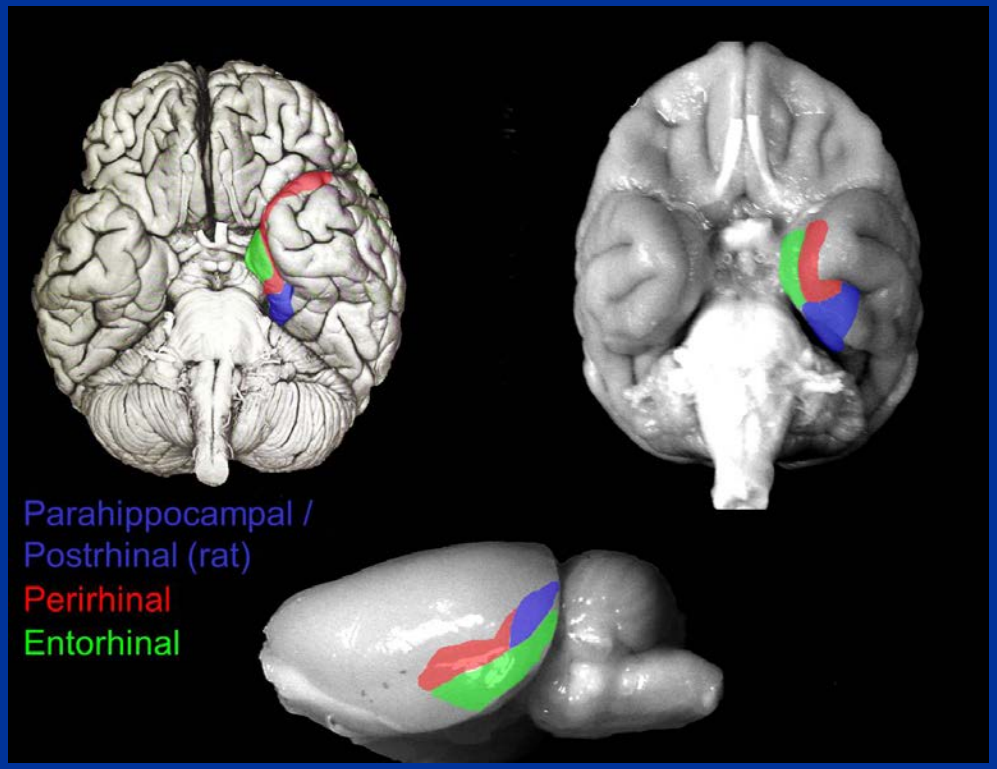
Parahippocampal /
Postrhinal (rat)
Perirhinal
Entorhinal

SCIENCE, VOL. 253 20 SEPTEMBER 1991

The Medial Temporal Lobe Memory System

LARRY R. SQUIRE AND STUART ZOLA-MORGAN

Studies of human amnesia and studies of an animal model of human amnesia in the monkey have identified the anatomical components of the brain system for memory in the medial temporal lobe and have illuminated its function. This neural system consists of the hippocampus

behavioral studies of rats, monkeys, and other animals with hippocampal lesions, which were initiated after patient H.M. was first described but which could not be easily interpreted in terms of impaired memory (*9*). In 1978, two alternatives were proposed to the view that the hippocampus itself is critical for memory functions. Horel proposed that memory functions were disrupted, not by

Characteristics

1. Memory is impaired on several tasks including ones identical to those failed by amnesic patients.

2. Memory impairment is exacerbated by increasing the retention delay or the amount of material to be learned.

3. Memory impairment is exacerbated by distraction.

4. Memory impairment is not limited to one sensory modality.

5. Memory impairment can be enduring.

6. Memory for events prior to the onset of amnesia can be affected (retrograde amnesia).

7. Skill-based memory is spared.

8. Immediate memory is spared.

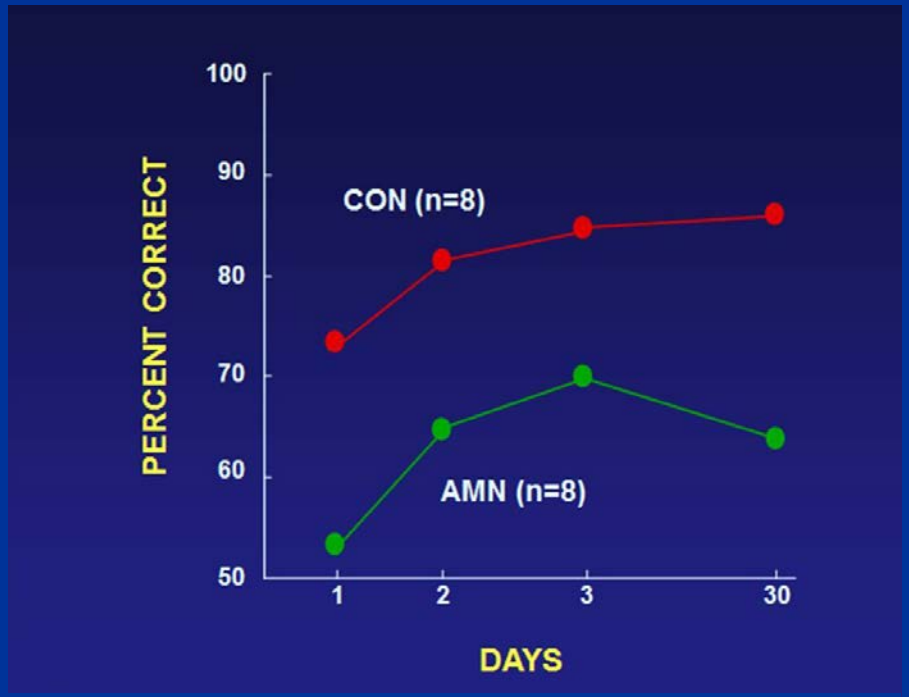

Squire et al, Behav. Neurosci., 1988

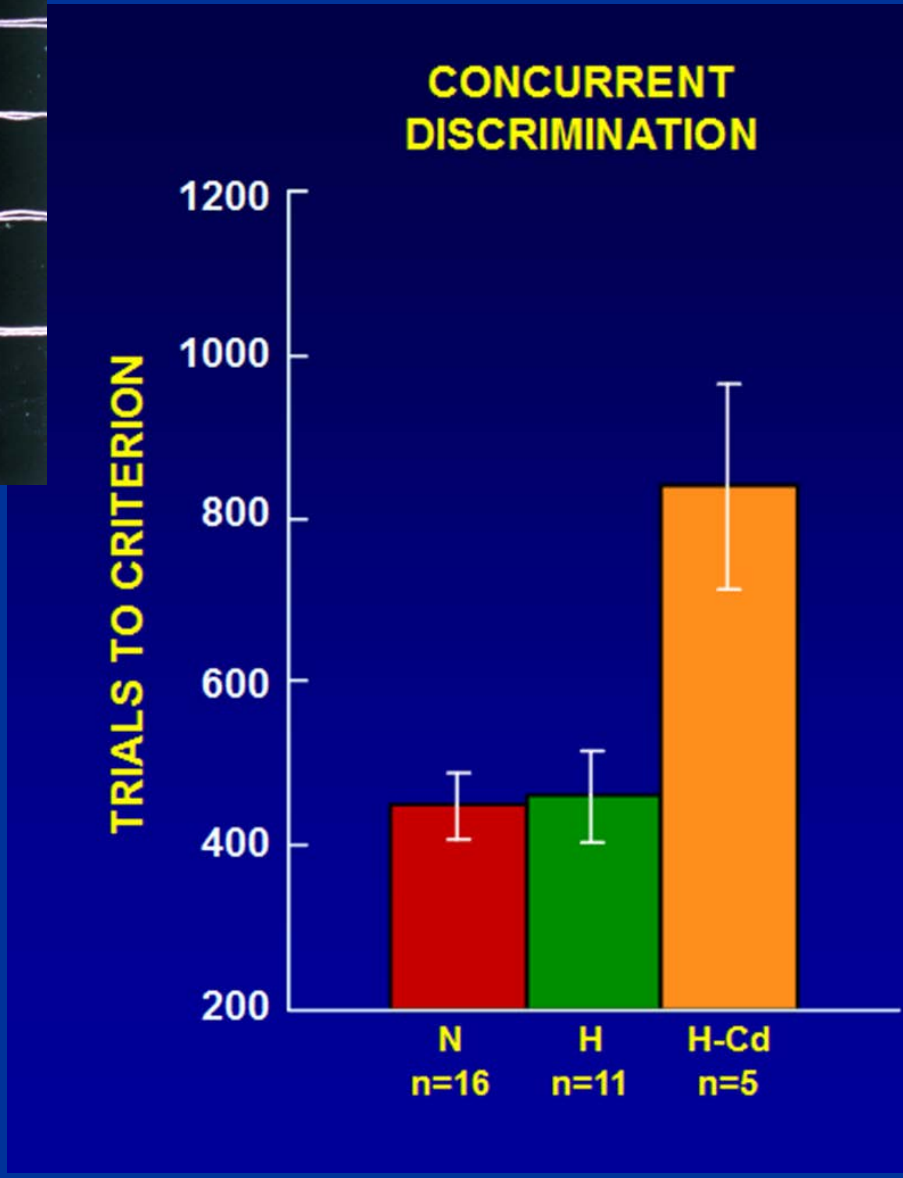

Teng et al, J. Neurosci., 2000

PATH INTEGRATION (HUMANS)

PATH INTEGRATION (HUMANS)

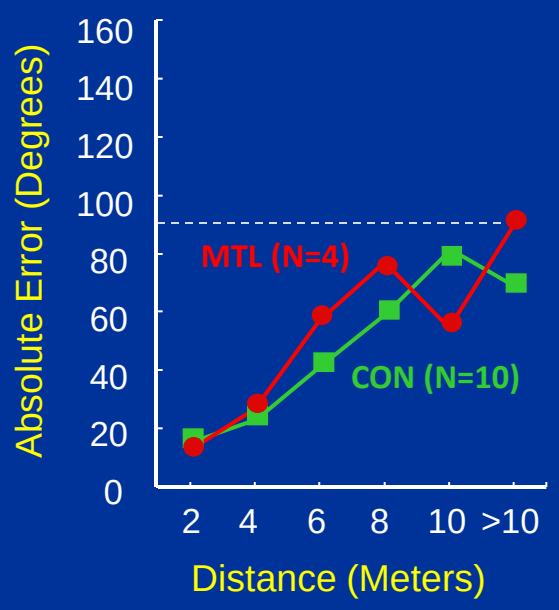

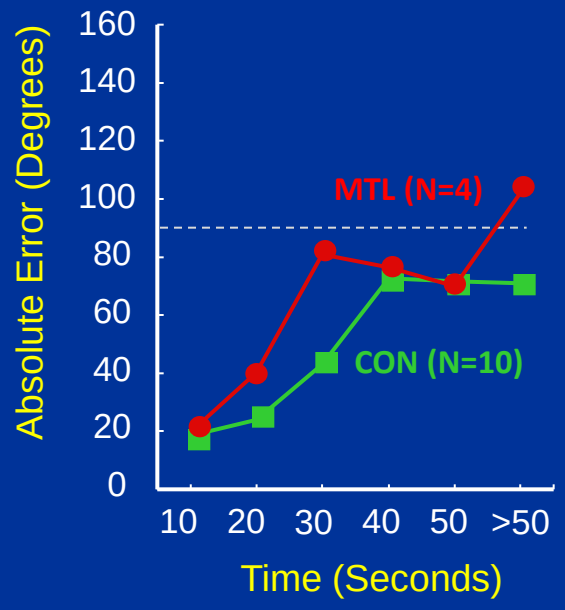

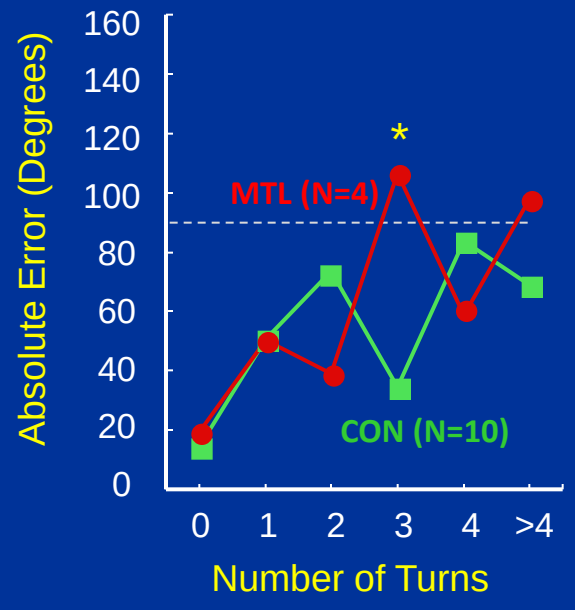

PATH INTEGRATION (RODENTS)

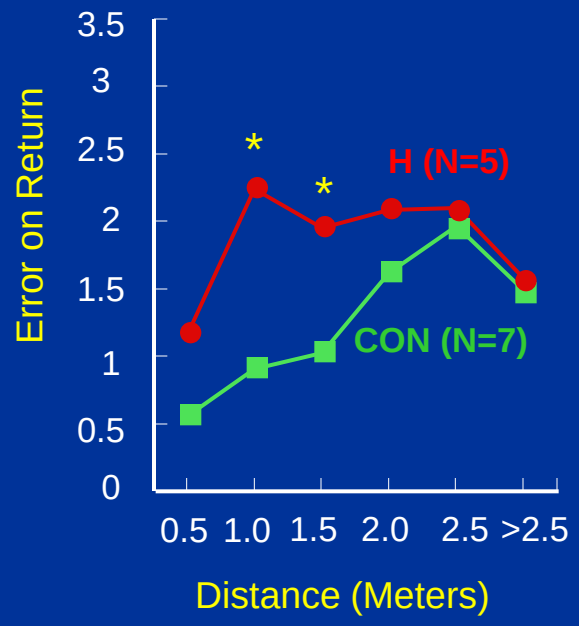

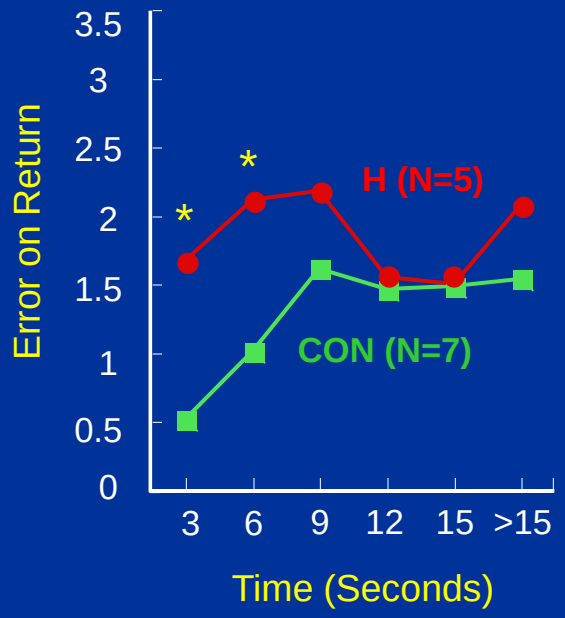

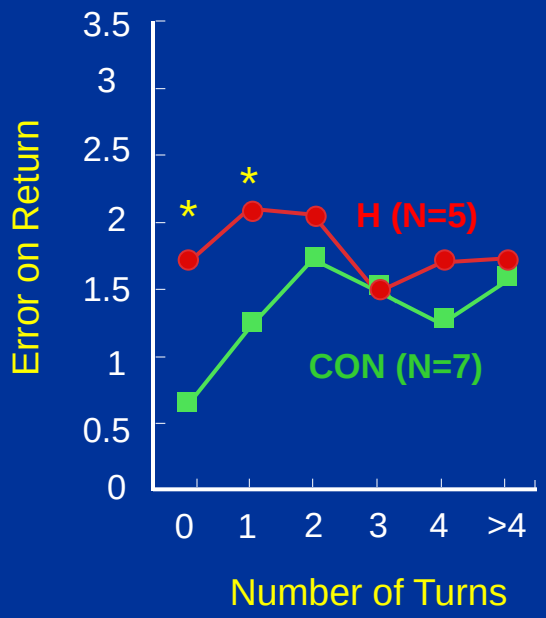
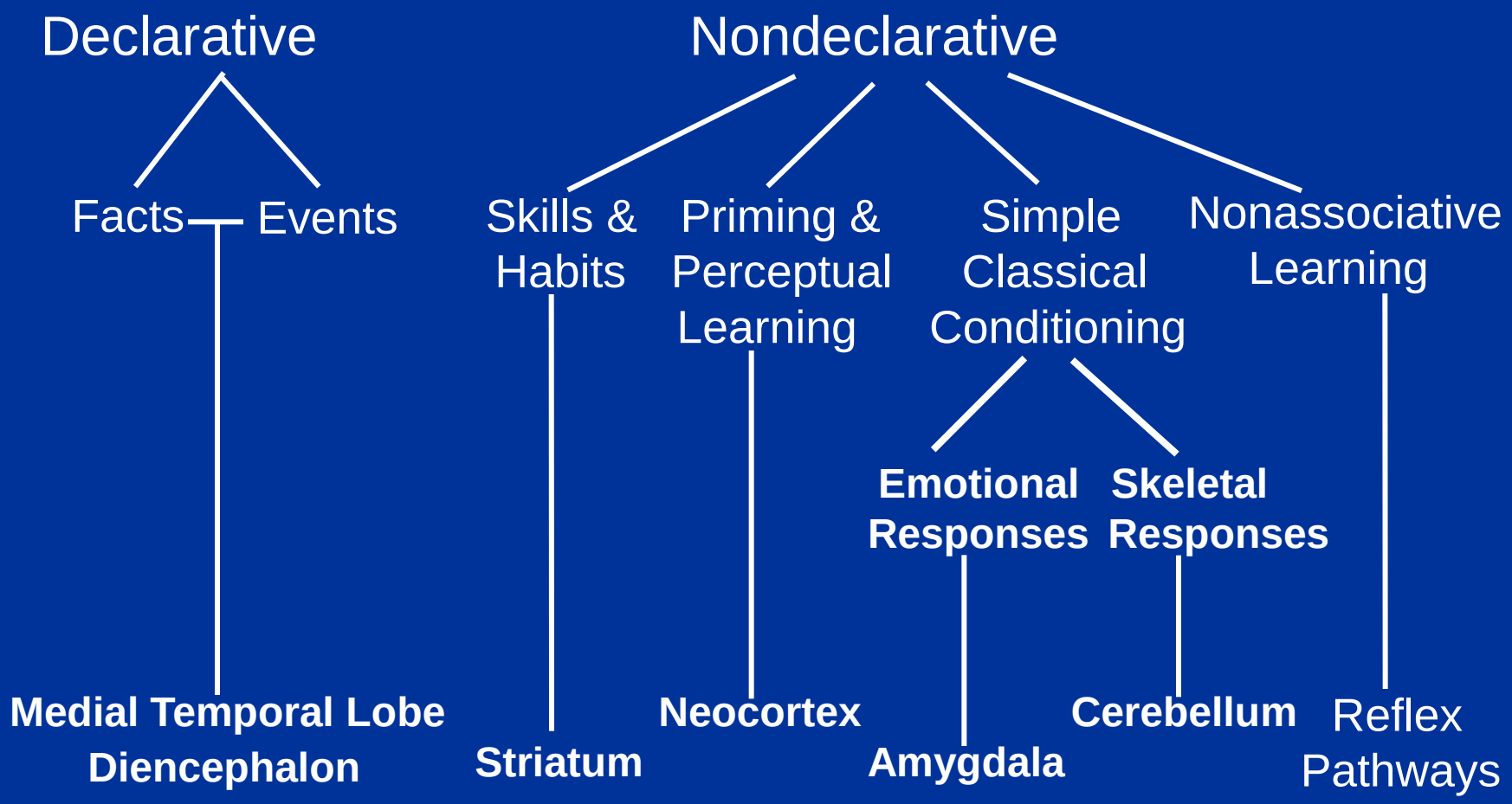
Long-Term Memory